

Contribution of Inferior Petrosal Sinus (Ips) Sampling in the Etiologic Diagnosis of Acth-Dependent Cushing's Syndrome.

Aem Haddam, Ns. Fedala*, L Ahmed Ali *, L Rabhi *

Department Of Diabetology Bab El Oued Hospital, Department Of Endocrinology Bab El Oued Hospital

I. Introduction

The development of inferior petrosal sinus sampling (IPS) is a high sensitivity and specificity in the positive diagnosis of Cushing disease when the pituitary imaging is normal or in the presence of adenoma with non-typical dynamic tests. It is a technique that alleviates the inadequacy of medical imaging to attest to the pituitary origin of a Cushing's disease (1).

It is an invasive technique that allows the detection of a gradient of hormonal concentration between the drainage system of the pituitary gland and a peripheral vein (central peripheral gradient) or between the petrous venous sinuses themselves (gradient Inter-sinus). Its disadvantages are exceptional complications. (2)

Objectif

Report IPS results of patients with ACTH-dependent hypercortisolism without adenoma visualization on hypothalamic hypophyseal magnetic resonance imaging (H H MRI)

Population, methodology

12 (8 F / 4H) patients of mean age 34 years (24-56) with ACTH-dependent hypercortisolism and without visualization adenoma on H H MRI have benefited from a IPS with calculation of Centroperipheral gradient and basal inter-sinuses of plasma ACTH

The diagnosis of corticotropic microadenoma was established in all patients on the basis of usual criteria:

(2 mg) and high doses (8 mg) of dexamethasone) demonstrating hypersecretion of cortisol (mean plasma cortisol: at 00H 284.80 nmol / L, before and after low-dose and high-dose dexamethasone suppression tests

(894.84 → 654.2 nmol / l, 986,76 → 544nmol/l) Mean plasma ACTH : 124pg / ml), radiological evidence of a tumor process and the existence of a Central-peripheral gradient ACTH after IPS (a baseline gradient greater than 2 was considered significant for the diagnosis of Cushing's disease)

Plasma concentrations of ACTH and cortisol were measured preoperatively and then for 7 days after surgery. Each patient also benefited from the production of a nuclear magnetic resonance (1.5 T) with injection of contrast agent (gadolinium IV). The cutting thickness was 3 mm.

Concerning the catheterization of the lower petrosal sinuses, simultaneous dosages of the plasma and petrous ACTH concentrations were performed at times 0, 7, 15 and 22 minutes to calculate the inter-sinus gradient, we used the hormonal concentrations measured at the 15th minute. We considered that a gradient of intersinus ACTH greater than 1.4 accounted for lateralization of the microadenoma on the side of the predominant secretion of the peptide. Conversely, a gradient less than 1.4 probably reflected a median or bilateral lesion.

The surgical procedure was performed transsphenoidally under microscopic control. If the adenoma was well visualized, the surgeon practiced an adenectomy. Otherwise, the adenoma was sought through an incision in the center of the gland and at its fins.

The tissue sampled was analyzed by optical and electron microscopy. Immunohistochemistry was performed with anti-ACTH, β TSH, GH, PRL LH, FSH and (alpha subunit (α SU).

II. Results

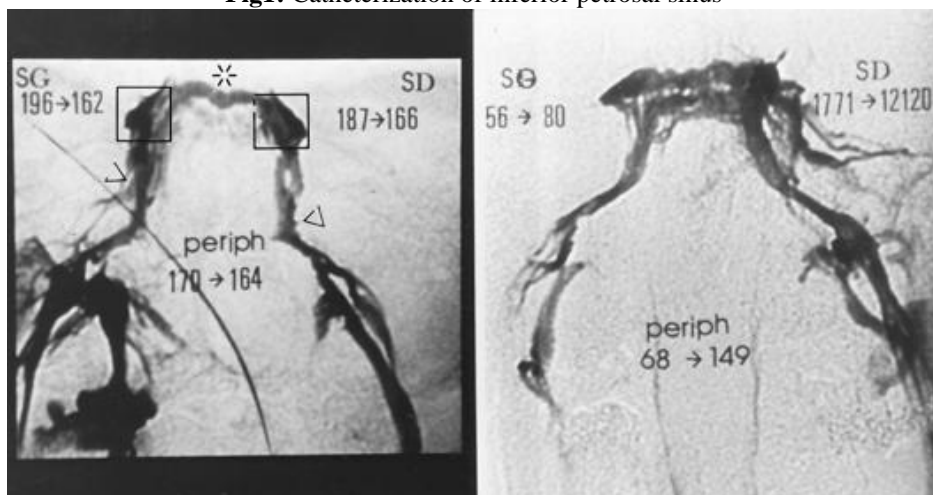
A centroperipheral gradient is observed in 9/12 ((75% , IPI+) (TABLE I).

Table I: Results of catheterization of inferior petrosal sinus (IPI +)

Mean ACTH (Normes :6,0 - 76,0 pg/mL)	Résultats
Central	124
Peripheral	32

A left lateralization is noted in 7/12 cases. The surgery allowed to find an adenoma in all the cases where the IPI was positive to the exception of a patient. The average tumor size is 2.6mm (2-4). The intersinus gradient coincided with the surgical results in 4 cases. In other cases, they were contralateral to the results of the IPI. All patients had remission after surgery. No serious complications were observed with the exception of a hematoma observed in three cases. The anatomopathology confirms an adenomatous tissue immunomarking ACTH in all cases. There was mixed ACTH, PRL and TSH secretion in 4 cases. After an average follow-up of 8 ± 0.12 years (0.5-10 years), patients were still in remission

Fig1: Catheterization of inferior petrosal sinus



III. Discussion

Cushing's syndrome (CS) results from chronic exposure to excessive glucocorticoids produced by the adrenal cortex. CS can be divided into two categories: adrenocorticotropic hormone (ACTH) -dependent (80-85%) and ACTH-independent (15-20%). Cushing's disease (CD) typically caused by a pituitary corticotroph adenoma; Ectopic ACTH syndrome frequently caused by an extrapituitary tumor. CD accounts for approximately 70% of cases of CS (2). The incidence of CD in the general population is estimated at 0.7-2.4 cases / million / year (6), and it affects women 3-5 times more often than men. Determining the etiology of CS is critical since it allows the choice of an appropriate therapeutic regimen because different etiologies have different treatments. Although CD is relatively rare, it most commonly affects adults ages 20 to 50 years. Therefore, the adenoma which is most often of small size, is a benign tumor. In 90% of cases, it is a microadenoma that can easily go unnoticed by MRI (3).

Hence, the diagnosis of CD is a rigorous process often requiring confirmatory tests at each step and endocrine consultation. Confirmation of the diagnosis of CS and accurate location of its source are vital to optimizing therapy to treat this complex disorder (1).

Catheterization of petrosal sinus introduced was introduced in 1977 by Corrigan (1). It quickly emerged as a technique to overcome the inadequacy of medical imaging to attest to the pituitary origin of a Cushing's disease. The sensitivity of this examination was secondarily improved by the stimulation of the pituitary by IV injection of CRH prior to the stepped venous sampling for hormonal assays (4). This dynamic stimulation made it possible, in many cases, to potentiate the value of a base centro-peripheral gradient considered to be at the limit of significance to confirm the pituitary localization of a microadenoma (5).

The measurement of the gradient between the inferior petrosal sinus themselves allows to predict lateralization of the adenoma within the gland (6). However, some series have raised interpretation biases regarding the prediction of lateralization (7). Anatomical vascular variations have been shown to affect hormone drainage and non-standard technical conditions may also influence the interpretation of the results of this approach (8)(9). Finally, more recently, the simultaneous measurement of other hormones (TSH, PRL, GH, alpha subunit of glycoproteins) in petrous samples has been proposed. This new approach was aimed to balance the asymmetry of pituitary venous drainage. In theory, an intersecting gradient close to 1 was to be obtained at these other hormones, which were not secreted by the adenoma themselves (10)(11).

IV. Conclusion

Diagnosis of Cushing's disease remains one of the most important challenges in clinical endocrinology. When the biological and neuroradiological results are not typical, a CSPI should be performed. This one is of an excellent diagnostic contribution

Provided that it is carried out by a trained team. The positioning of the catheters and the anatomical variations of the petrous sinuses can influence the result

Bibliographies

- [1]. Corrigan DF, Schaaf M, Whaley RA, Czerwinski CL, Earll JM. Selective venous sampling to differentiate ectopic ACTH secretion from pituitary Cushing's syndrome. *N. Engl. J Med* 1977 ; 296 : 861-2.
- [2]. Pivonello R, De Leo M, Cozzolino A, Colao A. The Treatment of Cushing's Disease. *Endocr Rev.* 2015 Aug;36(4):385-486.
- [3]. David N. Orth, M.D. Cushing's Syndrome
- [4]. *N Engl J Med* 1995; 332:791-803
- [5]. Allolio B, Gunther RW, Benker G, Reinwein D, Winkelmann W, Schulte HM. A multihormonal response to corticotropin-releasing hormone in inferior petrosal sinus blood of patients with cushing's disease. *J Clin Endocrinol Metab* 1990 ; 71 : 1195-1201.
- [6]. McNally PG, Bolia A, Absalom SR, Falconer-Smith J, Howlett TA. Preliminary observations using endocrine markers of pituitary venous dilution during bilateral simultaneous inferior petrosal sinus catheterization in Cushing's syndrome : Is combined CRF and TRH stimulation of value ? *Clinical Endocrinology* 1993 ; 39 : 681-686.
- [7]. Miller DL, Doppman JL, Nieman LK, Cutler GB Jr, Chrousos G, Loriaux DL et al. Petrosal sinus sampling : discordant laterali zation of ACTH-secreting pituitary microadenomas before and after stimulation with corticotropin – releasing hormone. *Radiology* 1990 ; 176 : 429-431.
- [8]. Doppman JL, Krudy AG, Girton ME, Oldfield EH. Basilar venous plexus of the posterior fossa : a potential source of error in petrosal sinus sampling. *Radiology* 1985 ; 155 : 375-378.
- [9]. Gorczyca W, Hardy J. Microadenomas of the human pituitary and their vascularization. *Neurosurgery* 1988 ; 22 (1) :1-6.
- [10]. Horvath E, Kovacs K, Scheithauer BW. Pituitary hyperplasia. *Pituitary* ; 1999 ; 1 (3-4) : 169-79.
- [11]. Loli P, Boccardi E, Branca V, Bramerio M, Barberis M, Losa M et al. Growth hormone and prolactin response to corticotropin-releasing-hormone in patients with Cushing's disease : a paracrine action of the adenomatous corticotrophic cells. *Clinical Endocrinology* 1998 ; 49 : 433-439.
- [12]. McNally PG, Bolia A, Absalom SR, Falconer-Smith J, Howlett TA. Preliminary observations using endocrine markers of pituitary venous dilution during bilateral simultaneous inferior petrosal sinus catheterization in Cushing's syndrome : Is combined CRF and TRH stimulation of value ? *Clinical Endocrinology* 1993 ; 39 : 681-686.